

Applications And Comparison of Medical Imaging Modalities

Dr.Shikha Jaiswal

Deptt Of Physics,Feroze Gandhi College, Raebareli.

Corresponding Author: Dr.Shikha Jaiswal

Abstract: Biomedical engineering is the application of the principles and problems-solving techniques of engineering to biology and medicine. This is evident throughout health-care, from diagnosis and analysis to treatment and recovery, and has entered the public conscience through the proliferation of implantable medical devices, such as pacemakers and artificial hips, to move futuristic technologies such as stem cell engineering and the 3-D printing of biomedical organs. In this paper, the application of electromagnetic waves involved in the different modalities like x-rays, ultrasound, computed tomography and MRI is reviewed, their perspectives to human life and the challenges ahead are studied. This paper presents a comparative study between the different medical imaging techniques, the concepts, benefits, risks and applications of these techniques will present with details.

Keywords: x-rays, ultrasound, computed tomography and MRI

Date of Submission: 15-11-2017

Date of acceptance: 23-12-2017

I. Introduction

Biomedical imaging constitutes a sub-discipline of biomedical engineering. Aspects of mechanical engineering, electrical engineering, chemical engineering, materials science, chemistry, mathematics, computer science and engineering are all integrated with human biology in biomedical engineering to improve human health. The main objective of biomedical imaging is to acquire a high resolution image with as much details as possible for the sake of diagnosis [Ali et.al 2008, AncaMorar 2010] [1,2]. In medical processing, the area of interest is being raised. It comprises an extensive range of methods and techniques, initiating with the acquisition of images by exploiting specialized devices, image enhancement analysis, to 3-D model reconstruction from 2-D images.

II. Modalities

The radiology experts use imaging modalities to take pictures of inside the body and to recognize areas of diseased or abnormal tissue. Imaging modalities allow providers to formulate a differential diagnosis. While selecting the type of modalities one should consider spatial resolution, temporal resolution, the field of view and the types of biological and physiological information possible on interaction between the imaging modality and intervention. [Gurpreetkaur, Rajdavinder Singh, 2014][3] The Types of Modalities studied are X-Ray, x-ray CT (computed Tomography) ultrasound and M R I (Magnetic Resonance Imaging). [Erik L. Ritman, et.al. 2006, Isuru Suranga Wijesinghe et.al., 2013][4,5]

a. X-Rays

X-rays are part of the electromagnetic spectrum with short wavelength and cause ionisation. They are absorbed by metal and bone but transmitted by healthy body tissue. These properties make them very useful for medical diagnosis and treatment. They affect the photographic film in the same way as visible light.

When the incident particle strikes a bound electron (the target electron) in an atom, the target electron is ejected from the inner shell of the atom. After the electron has been ejected, the atom is left with a vacant energy level, also known as a core hole. Outer shell electrons then fall into the inner shell, emitting quantized photons with an energy level equivalent to the energy difference between the higher and lower states. Each element has a unique set of energy levels, and thus the transition from higher to lower energy levels produces X-rays with frequencies that are characteristic to each element. When an electron falls from the L shell to the K shell, the X-ray emitted is called a K-alpha X-ray. Similarly, when an electron falls from the M shell to the K shell, the X-ray emitted is called a K-beta X-ray. Sometimes, however, instead of releasing the energy in the form of an X-ray, the energy can be transferred to another electron, which is then ejected from the atom. Thus, the Characteristic X-rays are emitted when outer shell electrons fill a vacancy in the inner shell of an atom, releasing X-rays in a pattern that is "characteristic" to each element as shown in Fig 1. Characteristic X-rays were discovered by Charles Glover Barkla in 1909, who later won the Nobel Prize in Physics for his discovery in 1917. Characteristic X-rays are produced when an element is bombarded with high energy particles, which can be photon, electrons or ions

(such as protons). When x-rays are directed into an object, some of the photons interact with the particles of the matter and their energy can be absorbed or scattered. This absorption and scattering is called attenuation. Other photons travel completely through the object without interacting with any of the material particles. The number of photons transmitted through a material depends on the thickness, density and atomic number of the material, and the energy of the individual photons [H. Kasban et.al 2015][6].

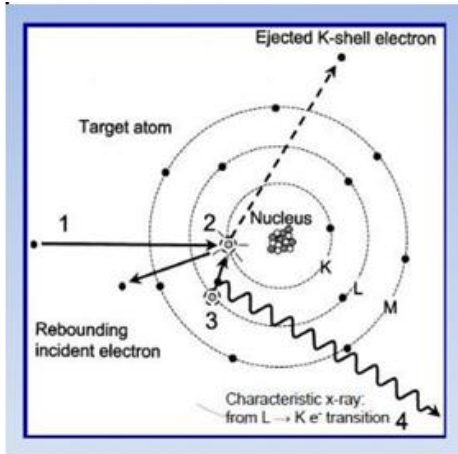


Fig 1 Production of X-rays

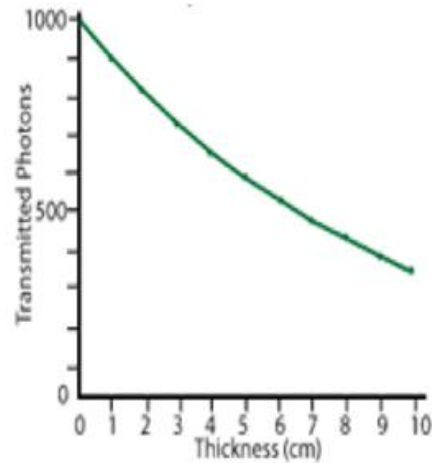


Fig 2 Transmitted photons vs thickness in x-rays

Even when they have the same energy, photons travel different distances within a material simply based on the probability of their encounter with one or more of the particles of the matter and the type of encounter that occurs. Since the probability of an encounter increases with the distance travelled, the number of photons reaching a specific point within the matter decreases exponentially with distance travelled as shown in Fig 2. Medical x-rays are used to generate images of tissues and structure inside the body. To create a radiograph, a patient is positioned so that the part of the body being imaged is located between an x-ray source and an x-ray detector. The x-ray chamber is shown in Fig 3. When x-ray machine is turned on, x-rays travel through the body and absorbed in different amounts by different tissues, depending on the radiological density of the tissues they pass through. Radiological density is determined by both the density and the atomic number of the materials being imaged. In older x-ray machines, white photographic film is placed behind the patient. X-rays pass through the patient's body and into the photographic film. The film turns black where x-ray hit it. Bones absorb x-rays, so the film stays white where the bones are. Fractures show the dark areas in the image of the bones on the film. Modern X-ray machines use CCDs instead of photographic film. The images are formed electronically, allowing them to be recorded and stored easily. The effective radiation dose for this procedure varies. Women should always inform their physician or x-ray technologist if they are pregnant. Bone x-rays are the fastest and easiest way for a physician to view and assess bone injuries, including fractures, and joint abnormalities, such as arthritis. It is particularly useful in emergency diagnosis and treatment. But there is always a slight chance of cancer from excessive exposure to radiation. However, the benefit of an accurate diagnosis far outweighs the risk.

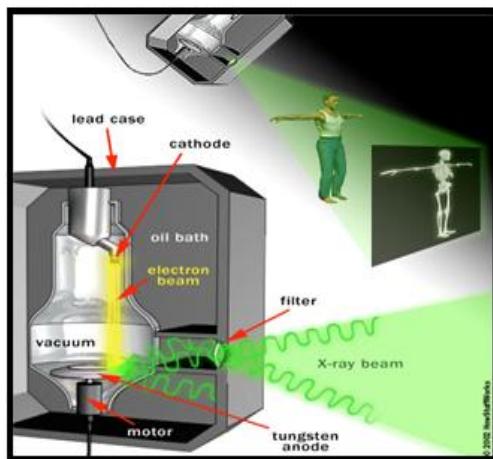


Fig 3 X-Ray chamber

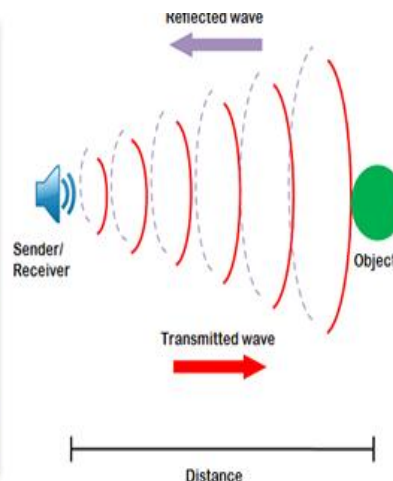


Fig 4 Transducer in ultrasound machine

b. X-Ray Computed Tomography (Ct Scan)

A 'computerized tomography' (CT) (or 'computerized axial tomography' (CAT) scan) uses a computer that takes data from several X-ray images of structures inside a human's or animal's body and converts them into pictures on a monitor. A CT scanner emits a series of narrow beams through the human body, producing more detail than standard single beam X-rays. Tomography is the process of generating a 2-dimensional image of a slice or section through a 3dimensional object. It is similar as looking at one slice of bread within the wholeloaf.CT scans to look for broken bones, blood clots, sign of heart disease, internal bleeding and cancers.

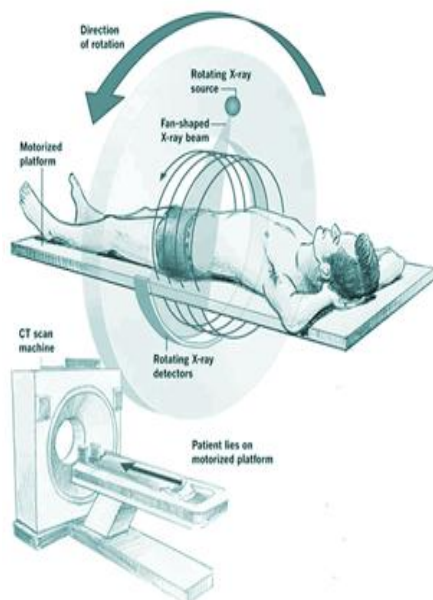


Fig 5 CT Scanner

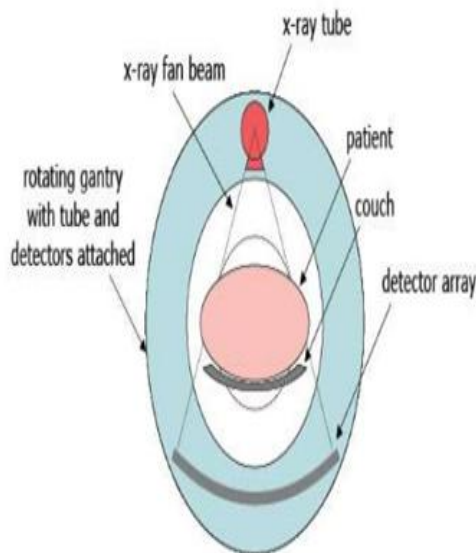


Fig 6 Component of CT Scanner

Unlike a conventional x-ray that uses a fixed x-ray tube a CT scanner uses a motorized x-ray source that rotates around the circular opening of a donut shaped structure called a gantry. During a CT scan, the patient lies on a bed that slowly moves through the gantry while the x-ray tube rotates around the patient, shooting narrow beams of x-rays through the body. Instead of film, CT scanners use special digital x-ray detectors, which are located directly opposite the x-ray source. X-ray detector which can see hundreds of different levels of density. It can see tissues inside a solid organ. This data is transmitted to a computer, which builds up a 3D cross-sectional picture of the part of the body and displays it on the screen. Sometimes a contrast dye is used because it shows up much more clearly on the screen. If a 3D image of the abdomen is required the patient may have to drink a barium meal. The barium appears white on the scan as it travels through the digestive system.[William Scarfe 2006][8]

The accuracy and speed of CT scans may be improved with the application of spiral CT. The X-ray beam takes a spiral path during the scanning it gathers continuous data with no gaps between images. For a spiral scan of the chest, for example, the patient will be asked to hold breathe for a few seconds.During a CT scan, exposure to ionizing radiation is there. The amount of radiation is greater than during a plain X-ray because the CT scan gathers more detailed information. CT scans have not been shown to cause long-term harm, although there may be a very small potential to increase risk of cancer.CT scans have many benefits that outweigh this small potential risk. Doctors use the lowest dose of radiation possible to obtain the needed medical information. Also, newer, faster machines and techniques require less radiation than was previously used.It involves injecting a dye into a vein in the arm followed by a CT scan. After a series of computation, the images of the heart, brain or the body part being scanned are obtained by the doctors and interpreted. A comprehensive report is then generated.It is non-invasive and does not require any hospitalization. The 320 Slice CT Scan is more accurate than the 64 Slice CT scan due to its superior image quality. It is simple, painless, super-fast and scans the heart in half a second. The shorter scan time provides comfortable breath holding, making this procedure ideal for people of all ages.The 320 Slice Heart CT scan can identify deposits on the walls of the heart blood vessels and indicate your vulnerability to Cardiac diseases.In cases of non-Cardiac chest pain, the 320 Slice Heart CT Scan can detect any other abnormality/body conditions causing the pain and facilitate the appropriate treatment.It is harmful to unborn baby and source of ionizing radiation and can cause cancer.

c. Ultrasound

Ultrasound is a type of imaging. In medicine, ultrasound is used to detect changes in appearance, size or contour of organs, tissues, and vessels or to detect abnormal masses, such as tumors the heart, blood vessels, kidneys, liver, and foetus. In an ultrasound examination, a transducer both sends the sound waves and receives the echoing waves.

Diagnostic ultrasound is able to noninvasively image internal organs within the body. However, it is not good for imaging bones or any tissues that contain air, like the lungs. Under some conditions, ultrasound can image bones (such as in a foetus or in small babies) or the lungs and lining around the lungs, when they are filled or partially filled with fluid.

One of the most common uses of ultrasound is during pregnancy, to monitor the growth and development of the foetus, but there are many other uses, including imaging the heart, blood vessels, thyroid, breast, abdominal organs and muscles.

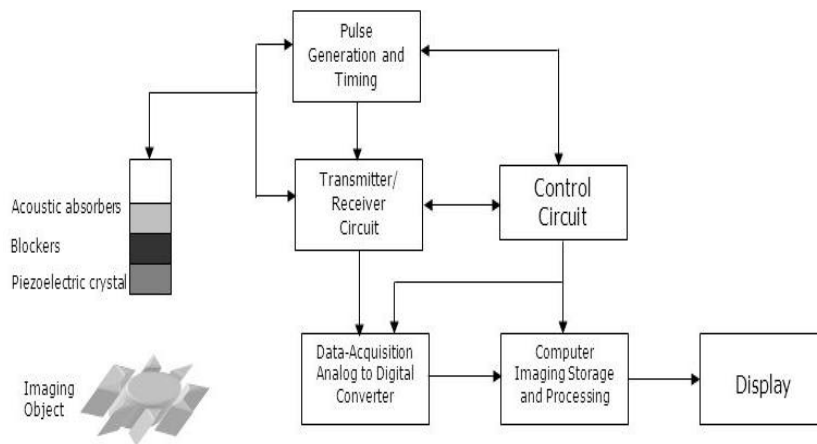


Fig 5 Schematic Diagram of conventional ultrasound imaging.

Ultrasound imaging uses high-frequency sound waves to look at organs and structures inside the body. Ultrasound imaging is based on the same principles involved in the sonar used by bats, ships and fishermen. When a sound wave strikes an object, it bounces back, or echoes. By measuring these echo waves, it is possible to determine how far away the object is as well as the object's size, shape and consistency (whether the object is solid or filled with fluid) as shown in Fig 4. When these echoes hit the transducer, they generate electrical signals that are sent to the ultrasound scanner. Using the speed of sound and the time of each echo's return, the scanner calculates the distance from the transducer to the tissue boundary. These distances are then used to generate two dimensional images of tissues and organs. [Mikael Tanter and Fink, 2014][7]

During an ultrasound examination, the technician applies gel to the skin. This keeps air pockets from forming between the transducer and the skin that blocks ultrasound waves from passing into the body. Diagnostic ultrasound is generally regarded as safe and does not produce ionizing radiation like that produced by x-rays. Still, ultrasound is capable of producing some biological effects in the body under specific settings and conditions.

d. Magnetic Resonance Imaging

MRI scanning uses magnetism, radio waves and a computer to produce image of body structures. MRI does not employ ionizing radiation but exploits radiofrequency (RF) fields when compared to the x-ray based medical diagnostic techniques. Therefore, than the ionizing radiation-based imaging modalities, the modality is considered to have less health effects [Kwan-Hoong et.al. 2003][9]. An MRI (or magnetic resonance imaging) scan is a radiology technique that uses magnetism, radio waves, and a computer to produce images of body structures. The MRI scanner is a tube surrounded by a giant circular magnet. The patient is placed on a moveable bed that is inserted into the magnet. The magnet creates a strong magnetic field that aligns the protons of hydrogen atoms, which are then exposed to a beam of radio waves. This spins the various protons of the body, and they produce a faint signal that is detected by the receiver portion of the MRI scanner. The receiver information is processed by a computer, and an image is produced.

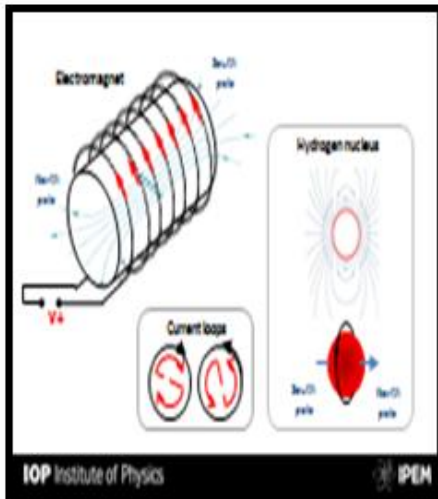


Fig.7.1 Magnetic field

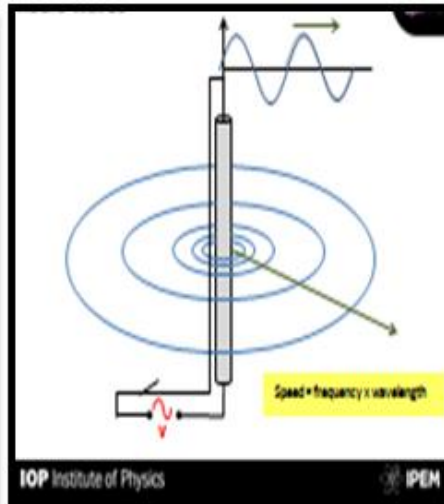


Fig.7.2 Radio waves

When the body is placed in a strong magnetic field, such as an MRI scanner, the protons' axes all line up. This uniform alignment creates a magnetic vector oriented along the axis of the MRI scanner. Fig 7.3 shows the MRI scanner. They come in different field strengths, usually between 0.5 and 1.5 tesla. When additional energy (in the form of a radio wave) is added to the magnetic field, the magnetic vector is deflected. The radio wave frequency (RF) that causes the hydrogen nuclei to resonate is dependent on the element sought (hydrogen in this case) and the strength of the magnetic field. The strength of the magnetic field can be altered electronically from head to toe using a series of gradient electric coils, and, by altering the local magnetic field by these small increments, different slices of the body will resonate as different frequencies are applied.

When the radiofrequency source is switched off the magnetic vector returns to its resting state, and this causes a signal (also a radio wave) to be emitted. It is this signal which is used to create the MR images. Receiver coils are used around the body part in question to act as aerials to improve the detection of the emitted signal. The intensity of the received signal is then plotted on a grey scale and cross sectional images are built up. Multiple transmitted radiofrequency pulses can be used in sequence to emphasise particular tissues or abnormalities. A different emphasis occurs because different tissues relax at different rates when the transmitted radiofrequency pulse is switched off. The time taken for the protons to fully relax is measured in two ways. The first is the time taken for the magnetic vector to return to its resting state and the second is the time needed for the axial spin to return to its resting state. The first is called T1 relaxation, the second is called T2 relaxation.

An MR examination is thus made up of a series of pulse sequences. Different tissues (such as fat and water) have different relaxation times and can be identified separately. By using a “fat suppression” pulse sequence, for example, the signal from fat will be removed, leaving only the signal from any abnormalities lying within it.

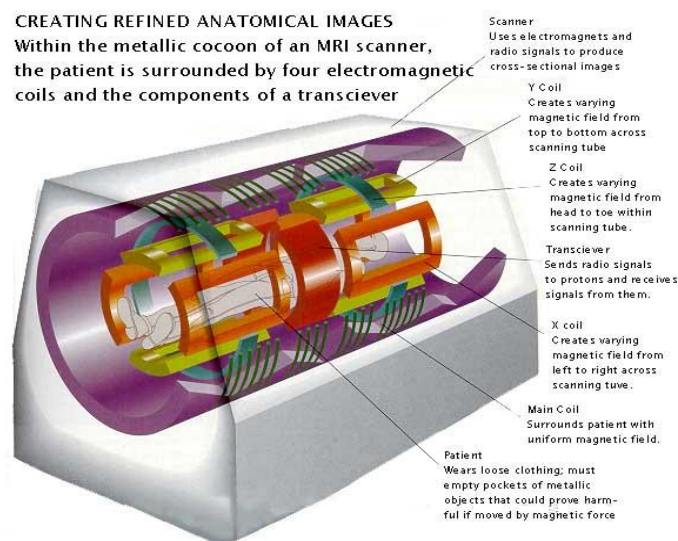


Fig 7.3 MRI Scanner (taken from Ref 17)

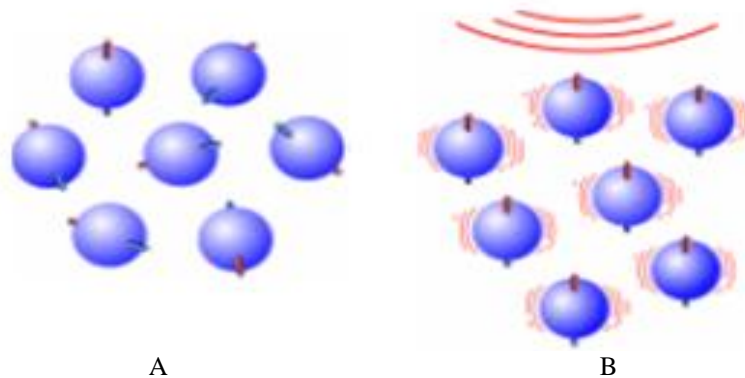


Fig7.4 Protons under normal circumstances. **Fig 7.5** Protons under strong magnetic field

The hydrogen proton can be likened to the planet earth, spinning on its axis, with a north-south pole. In this respect it behaves like a small bar magnet. Under normal circumstances, these hydrogen proton “bar magnets” spin in the body. When the body is placed in a strong magnetic field, such as an MRI scanner, the protons axes all line up. This uniform alignment creates a magnetic vector oriented along the axis of the MRI scanner. There are no known biological hazards of MRI because, unlike x-ray and computed tomography, MRI uses radiation in the radio frequency range which is found all around us and does not damage tissues as it passes through. Functional Magnetic Resonance Imaging [fMRI] is a type of MRI that allows and absorb the brain activity. By fMRI mapping of the brain, we can see how brain carries out mental task and what parts of the brain are responsible for different brain disorders.

The powerful magnetic fields generated by the MRI scanner will attract metal objects, often with great force. For this reason, there is instruction to remove all metallic belonging, such as watches, keys and jewellery. MRI refers for the unborn child (foetus) than imaging with X-Ray or CT scans. However, MRI scans can cause slight warning of the body.

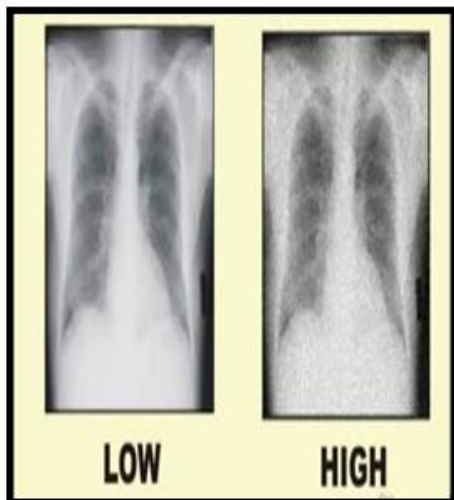


Fig 8.1 Noise in Images

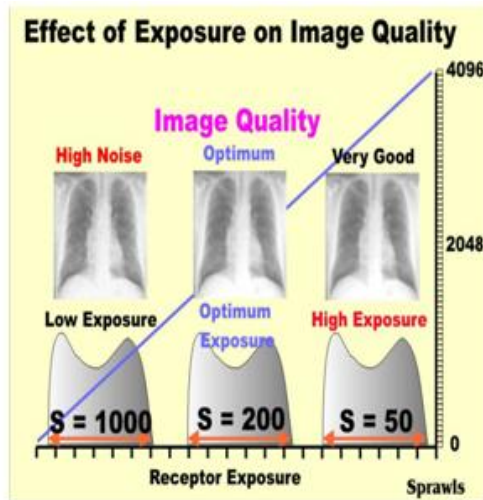


Fig 8.2 Effect of exposure on images.

III. Challenges

One of the major challenges in the study of medical imaging is noise removal in these digital images. [Yang Wang AndHaomin Zhou, 2006][10]It is necessary that medical images be sharp, clear and free of noise. The random variation in image brightness is designated noise as shown in Fig 8.1. All medical images contain some visual noise. The presence of noise gives an image a mottled, grainy, textured, or snowy appearance. Image noise comes from a variety of sources. No imaging method is free of noise, but noise is much more prevalent in certain types of imaging procedures than in others. Although noise gives an image a generally undesirable appearance, the most significant factor is that noise can cover and reduce the visibility of certain features within the image as shown in Fig 8.3. The loss of visibility is especially significant for low contrast objects. The visibility threshold, especially for low contrast objects, is very noise dependent. In principle, when we reduce image noise, the "curtain" is raised somewhat, and more of the low contrast objects within the body become visible.

IV. Conclusion

The modalities are very important for diagnosis. In analysis methods and computer-aided diagnosis, the rapid progress in computerized medical image reconstruction, and the associated developments, has propelled medical imaging. The biomedical imaging such as x-ray [radiography], ultrasound, CT [computed tomography], MRI [magnetic resonance imaging] helps to detect the tiny changes of structures within the body. From the discussion it is clear that no technique is individually reliable.

References

- [1]. Ali, El-Dokany, Saad and Abd El-Samie, "Curvelet Fusion of MR and CT Images", Progress In Electromagnetics Research, Vol. 3, pp.215–224, 2008.
- [2]. AncaMorar, FloricaMoldoveanu, AlinMoldoveanu, Victor Asavei And AlexandruEgner, "Medical Image Processing in Hip Arthroplasty", Wseas Transactions On Signal Processing, 2010.
- [3]. Gurpreetkaur, Rajdavinder Singh, Image enhancement and its techniques, (IJCTT) vol 12 no 3 Jun 2014
- [4]. Erik L. Ritman Medical X-Ray Imaging, Current Status And Some Future Challenge JCPDS 2006.
- [5]. IsuruSurangaWijesingheImage Processing in Bio-medical Area DOI 10.13140/RG.2.1.1254.1680, 2013.
- [6]. H. Kasban M. A. M. El-Bendary and D. H. Salama, A Comparative Study of Medical Imaging Techniques, International Journal of Information Science and Intelligent System, 4(2): 37-58, 2015.
- [7]. Mikael Tanter and Fink, Ultrafast imaging in biomedical ultrasound, ieeexplore, 2014.
- [8]. William Scarfe, FRACDS, Allan Farman and PredagSukovic, "Clinical Applications of Cone-Beam Computed Tomography in Dental Practice", JCDA, Vol.72.No.1,2006.
- [9]. Kwan-Hoong, Azlan Ahmad, Nizam and Abdullah, "Magnetic Resonance Imaging: Health Effects and Safety", Proceedings of the International Conference on Non-Ionizing Radiation at UNITEN, Electromagnetic Fields and Our Health, 2003.
- [10]. Yang Wang AndHaomin Zhou, "Total Variation Wavelet Based Medical Image De-noising", International Journal of Biomedical Imaging, Vol. 2006.

Dr.Shikha Jaiswal. "Applications And Comparison of Medical Imaging Modalities." International Journal of Engineering Science Invention (IJESI), vol. 07, no. 01, 2018, pp. 94–100.