

Disease Severity Based On Areas of Exudates, Blood Vessels and Micro-Aneurysms in Retinal Fundus Images Using K-Means Clustering

Dr. P.V.Ramaraju¹, I.H.S.Manisree²

¹HOD ,S.R.K.R Engineering College, Bhimavaram, India

² PG student ,S.R.K.R Engineering College, Bhimavaram, India

Corresponding Author: Dr. P.V.Ramaraju

ABSTRACT: Diabetic retinopathy (DR) is a kind of disease that attacks retina of human eye occurs mainly due to diabetes because of diabetes there is elaboration of sugar levels in body. Due to DR Patient losses his vision; earlier exposure can diminish the complication of visual deterioration. Existence of micro-aneurysms, cotton-wool spots, hemorrhages and exudates are indication of DR. Micro aneurysms and exudates are foremost signs of DR and can be blocked with a recent diagnosis. Digital fundus image collected from fundus camera helps in analyzing the exudates and micro-aneurysms in prior way. This thesis proposes a method which has two essential steps they are coarse segmentation executed by k-means clustering and fine segmentation executed by morphological image processing for disclosure of required features such as exudates, micro-aneurysms and blood vessels on retinal images of very low contrast. Initially pre-processing of retinal images are performed. Later segmentation of the processed images is done through K-Means clustering. In order to specify these segmented regions into Non-Exudates (blood vessels and micro aneurysms) and Exudates a special set of features which are based on colour and texture are derived from Morphological operations are done to acquire the perfect classification. As disclosure of exudates, and micro aneurysms existing in limited areas can easily identified using this technique hence this technique appears encouraging. Depending upon the area of exudates, blood vessels and micro aneurysms disease severity can be explained whether it is mild or in severe stage.

KEYWORDS: Fundus images, micro-aneurysms, exudates, hamorrhages, k-means clustering.

Date of Submission: 09-02-2018

Date of acceptance: 24-02-2018

I. Introduction:

Patients suffering with diabetes have a vast chance of losing their vision. First and foremost diabetes mainly occurs due to increase sugar levels (glucose) in body. As diabetes affects many parts of human body including eyes. One can say the eyes of a person are healthy only when the blood vessels are working properly. In general, blood vessels bring oxygen and other nutrients from different parts of body this includes very tiny blood vessels will nourish the retina. The most common eye problem for people with diabetes is a condition called diabetic retinopathy(DR). Because of DR,high levels of sugar in the blood can cause changes to the retina blood vessels[1]. Micro-aneurysms are the early stage identification of the disease blood release from the retinal blood vessels later exudates ,hemorrhages are identified. Exudates are yellowish-white lesions released from the blood vessels and hamorrhages is escape of blood from blood vessels in huge way. If this bleeding happens in front of the retina it can prevent light from reaching it.This can cause problems such as blurry vision, floating spots if not treated. Detection of DR,by ophthalmologist through manual screening is complicated so in order to reduce this problem automatic screening is performed which increases the observation and operation on thousand of images done easily.

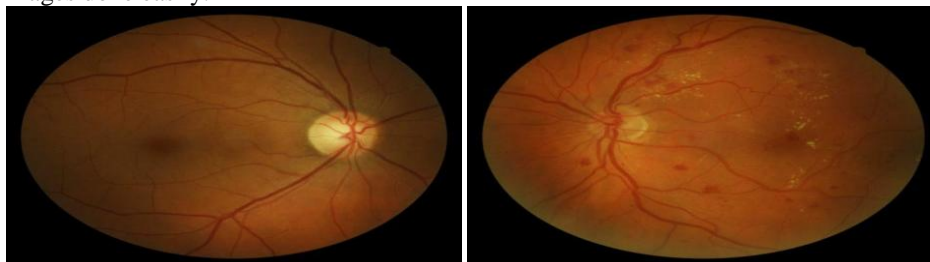

Fig.1:Healthy retina(left) and Diabetic Retinopathy(DR) effected eye (right)

II. Methodology

In detection of exudates, micro-aneurysms and blood vessels all the three detection methods follow the same steps up to image segmentation. Later according to their identification process next steps are identified.

1 Exudates detection:

Raw fundus images are obtained before performing the main operation six main steps have to be concentrated they are 1. Pre-processing 2. Anatomical features extraction 3. Image segmentation (K-means clustering) 4. Exudates extraction 5. Filtering of dark features 6. Exudates detection.

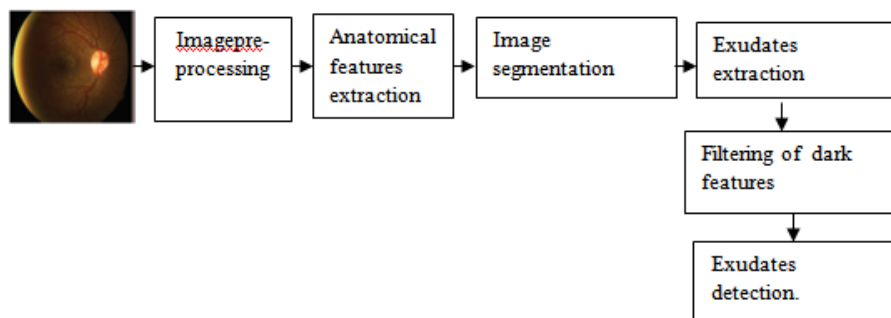
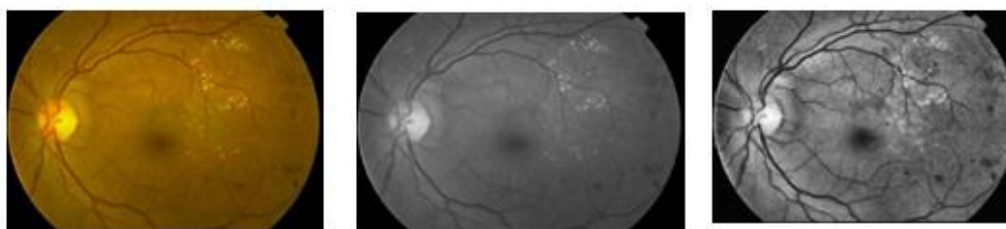


Fig 2. Block diagram of micro-aneurysms detection

1.1 Image pre-processing:

Image pre-processing means processing of image before main processing starts. To improve image data quality for later analyses. Removing of sensor generated noise and atmospheric influences. In image pre-processing we alter image pixel values permanently. In this process we have three stages as: Gray scale conversion, Image enhancement, Image denoising. All these processes are done to make the image suitable for further proceedings.



3(a): Input retinal image 3(b): Gray scale conversion image 3(c): Contrast enhanced image

3(a): Input retinal image 3(b): Gray scale conversion image 3(c): Contrast enhanced image

Fig.3: Pre-processing results

1.2 Anatomical feature extraction:

Anatomical features are the unwanted parts present in eye such as optic disc, macula etc., should be extracted so that the exudates are detected without any objection [4]. And the main feature of exudates is perfectly detected.

1.3 Image segmentation:

Segmentation is the process of partitioning a digital image into multiple segments (sets of pixels, also known as super-pixels). The goal of segmentation is to simplify and/or change the representation of an image into something that is more meaningful and easier to analyze. The result of image segmentation is a set of segments that collectively cover the entire image, or a set of contours extracted from the image.

➤ **K-means clustering:** The process of arranging similar objects into one group and remaining to their corresponding groups is called clustering. Splitting of n-objects into k-clusters in which the n-objects comes under the cluster based upon the mean nearer to it. Now k-different clusters are identified in this method which has largest possible distinction.

Objective function

$$(J) = \sum_{j=1}^k \sum_{i=1}^n \|x_i^{(j)} - c_j\|^2 \quad (A)$$

Algorithm:

1. The data is clustered into k-groups here k is predefined.
2. Cluster centres are identified randomly and select k-points.
3. According to Euclidean distance function objects are assigned to their closest centre.
4. Now, in cluster mean or centroid of all objects are calculated.

5. Repeat steps 2,3,4, until the clusters is filled with same points in consecutive rounds.

1.4 Exudates extraction:

Morphological closing which consists of dilate followed by erode is applied to removed the blood vessels. The dilate function expands the exudates area while erode function removes the blood vessels as shown in fig.4(a).

$$M_{Closing} = closing(M_B) \tag{1}$$

M_B = Gray scale retinal image

The image Fig.4(a) is then converted to double-precision value for function “colfilt” to mark the exudates region before converted back to uint8 as shown in Fig.4(b). This image is converted back to binary using the function “im2bw” with a threshold value to filter out the exudates.

$$M_{colfilt} = colfilt(M_{Closing}, [66], 'sliding', @var) \tag{2}$$

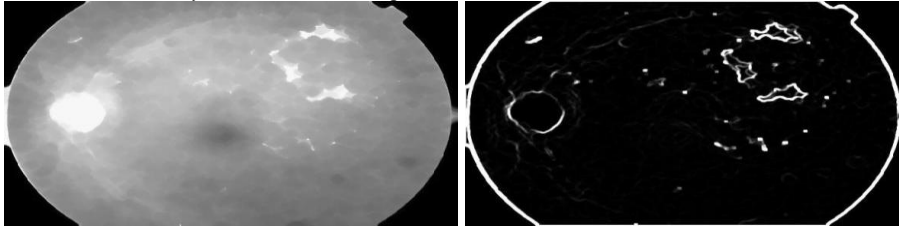


Fig.4(a): Image after Morphological closing 4(b): Image after column filter closing

The location of the optical disk is detected by the brightest point(s) on the grayscale image. It is usually the maximum value and a circular mask is then created to cover it.



Fig 4(c):Mask for the Optical Disk 4(d):Image with Optical Disk removed

The regions of the exudates are obtained after the removal of the circular border. Morphological closing is then applied to the image. The dilate function is to fill the exudates while erode function is to expand their sizes.



Fig 4(e):Regions of exudates 4(f):Image after Morphological closing

1.5 Filtering of the dark features:

Non-exudates (dark features) are extracted from the grayscale image using function “im2bw” and are represented as binary 1 (white) after intensity inversion.



Fig 5: Image with Dark features (represented as white)

Now by performing AND logic exudates are identified.

1.6 Exudates detection:

AND logic is used to remove noise for the detection of exudates. Regions with exudates are marked out after applying column filter but this includes non-exudates such as hemorrhages and has to be removed as noise.

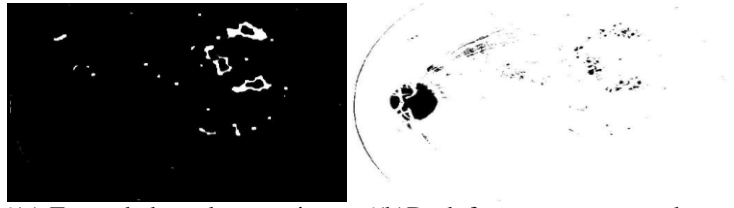


Fig 6(a): Expanded exudates regions after Morphological closing 6(b) Dark features represented as white.

By removing the non-exudates from the detected regions, the exudates can be determined. Image segmentation is applied to the grayscale image to extract the bright spots for comparison. These areas (bright features) are represented by binary 0 (black) while the non-exudates (dark features) are represented as binary 1 (white) as shown in Fig.6 (b)

By applying AND logic to Fig.6(a) and Fig.6(b), the non-exudates regions are set to set to binary 0 (black) and removed when the pixels for both images are binary 1 (white). As a result, the exudates area is obtained. Now the area of the exudates are calculated by considering the easy technique of detecting the diseased area parts and corresponding area is obtained by applying for loop for presence of pixels is considered as 1(white) and dark part as 0(black).

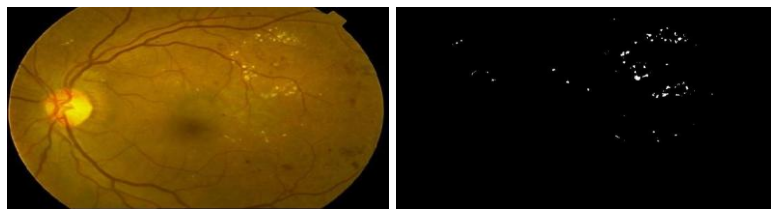


Fig 7: Fundus image (Left) with its exudates image (Right)

2 Blood vessels detection:

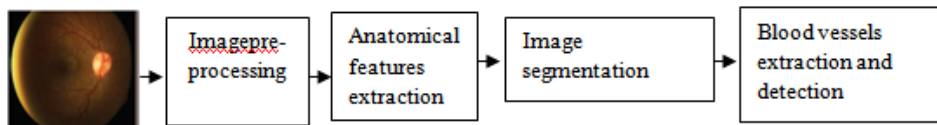


Fig 8: Block diagram of blood vessels detection

As like in exudates the same process is carried in blood vessels detection up to image segmentation using k-means clustering later the process gets changed for extraction and detection.

2.1 Extraction and detection of blood vessels:

The fundus image is first pre-processed to standardize its size. The intensity of the gray scale image or green channel is then inverted before adaptive histogram equalization is applied [5].

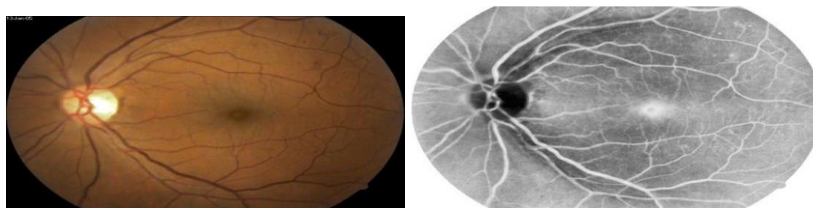

Fig 9(a): Original fundus image 9(b): Inversed image after histogram equalization

The optical disk is a black patch in the image as shown at Fig.9(b) Morphological opening which consisted of erode followed by dilate is applied. Erode function protects the small blood vessels by reducing their sizes while dilate function blows up the larger remaining details which are intended to be removed.

$$M_{opening} = opening(M_R) \quad (3)$$

M_R = Original retinal image

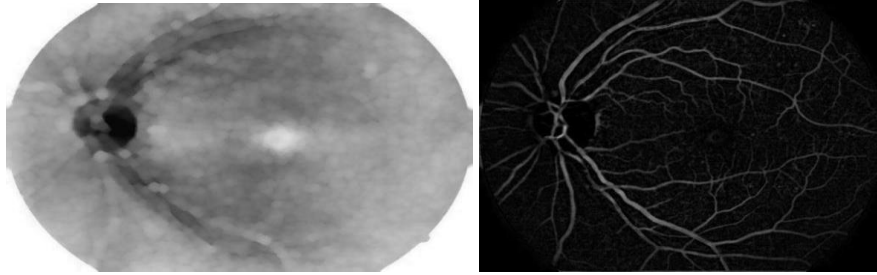


Fig 9(c): Image after Morphological opening 9(d): Image after optical disc removed

The optical disk is then removed by subtracting Fig 9(b) with Fig 9(c)

The image Fig 9(d) is then converted to a binary image using the function “im2bw”. The pixels of the input image are converted to binary 1 (white) for values greater than the selected threshold and to binary 0 (black) if otherwise. The converted binary image Fig 9(e) at this point is still noisy and function “bwareaopen” is applied remove the small area of pixels considered to be noise.

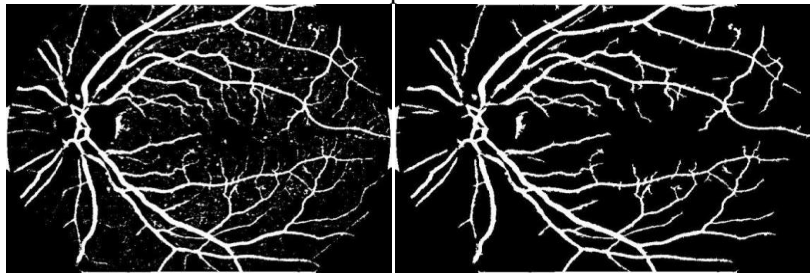


Fig 9(e) Binary image after Image segmentation 9(f): Blood vessels after removal of “noise”

The green component image Fig 9(a) is also applied with adaptive histogram equalization thrice and image segmentation to select the blood vessels area. Small pixels which are considered as noise are also removed.

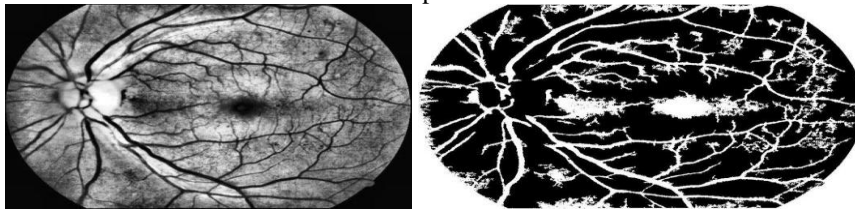


Fig9(g) Image after histogram Equalization Fig.9(h) Blood vessels after image segmentation and removal of “noise”

The image fig 9(h) is combined with the mask and compared with the earlier blood vessel image Fig 9(f) using AND logic. The similar pixels are output as binary 1 (white) and represent the blood vessels.



Fig 9(i): Mask at the optical disk area 9(j): Combined image after removing “noise”
The final blood vessels image Fig 9(k) is obtained after the removal of the circular border.

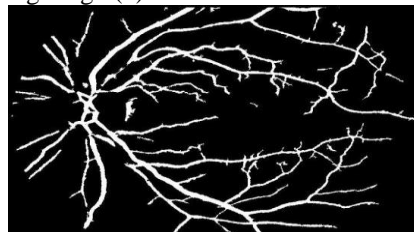


Fig 9(k): Image of Blood vessels

2.2 Experimental procedure - AND logic:

Two methods of detecting the blood vessels are used. Both methods would generally detect different locations of the images like exudates as blood vessels; hence by computing their similarity, the non blood vessels area could be filtered.

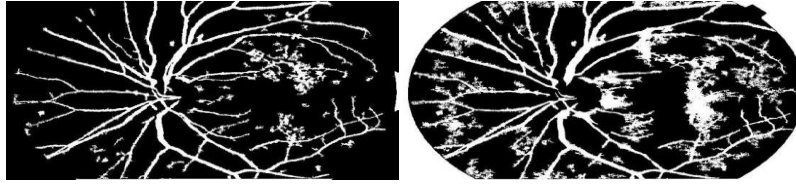


Fig 10(a): Comparing blood vessels images obtained

AND logic is applied to mark out the similar pixels of the two images. The output pixel is registered as binary 1 (white) when the both images' pixels are binary 1 (white). The obtained image would be a clearer blood vessels image.

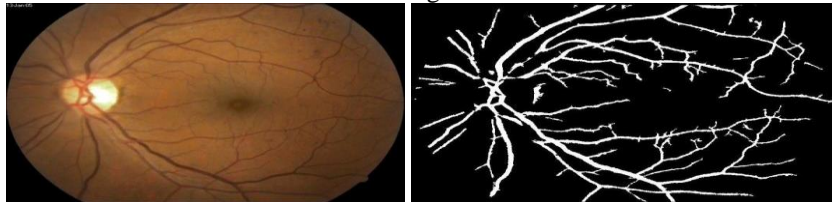


Fig 10(b): Fundus image (Left) with its blood vessels image (Right)

III. Micro-Aneurysms Detection:

Raw fundus images are obtained before performing the main operation six main steps has to be concentrated

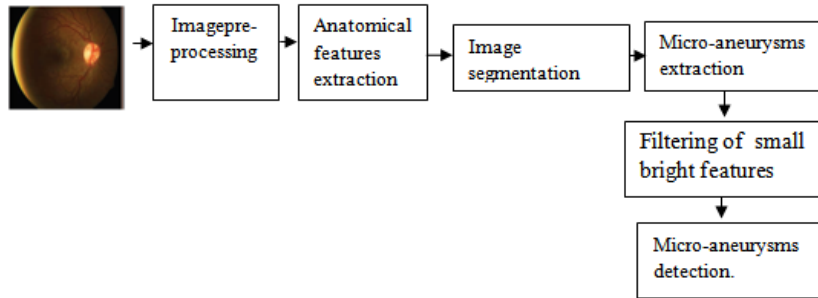


Fig 11. Block diagram of micro-aneurysms detection

Those six steps are 1.Pre-processing 2.Anatomical features extraction 3.Image segmentation(K-means clustering) 4.Micro-aneurysms extraction 5.Filtering of small bright features 6.Micro-aneurysms detection.

3.1 Micro-aneurysms extraction:

Now in order to extract the micro-aneurysms the contrast stretched image obtained by histogram equalization as shown in fig.3(c) has to undergo with application of 'canny method' for edge detection[7].

$$M_{CS} = M_{AHE}(M_B) \quad (4)$$

Where, M_{CS} = Contrast stretched image, M_{AHE} = Adaptive histogram equalization, M_B = Gray scale retinal image. Canny method is applied to detect the outlines of the image hence considering transformation image of M_{FB} with frudge factor α_F of 0.5.

$$M_{Canny} = M_{FB}(\alpha_F) \quad (5)$$

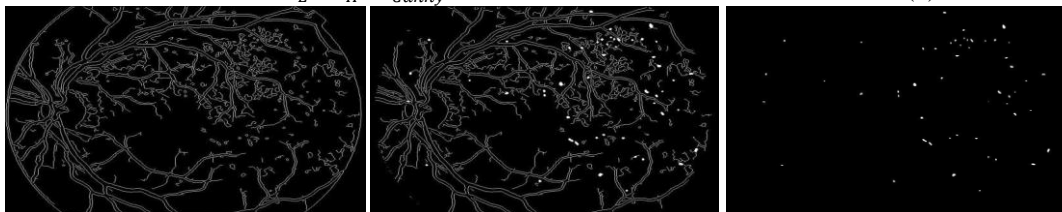
After application of canny method, the lesions or red dots has to be detected by filling them hence 'imfill' is used to fill the lesions.

$$M_H = \text{imfill}(M_{Canny}, \text{'hole'}) \quad (6)$$

M_H = Image obtained by filling the holes in canny image.

Filtering of lesions done by subtracting the M_{Canny} with M_H and resulted image is denoted as M_L .

$$M_L = M_H - M_{Canny} \quad (7)$$



12(a): Image of edges 12(b): Image after function 'imfill' 12(c): Image after removing large area
fig 12: Micro-aneurysms extraction

3.2 Filtering of small bright features:

Other than micro-aneurysms like exudates, blood vessels which are not the required features are also detected as shown in fig.4(c) Hence it is necessary to filter those features.

Initially from fig.4(c) contains exudates, micro-aneurysms and blood vessels to obtain these unwanted features separately and to get required feature i.e., micro-aneurysms the gray scale enhanced image fig. 3(b) is undergone with adaptive histogram equalization twice to obtain the bright features present in the image which are not but exudates.

$$M_{DAHE} = \text{doubleAHE}(M_B) \quad (8)$$

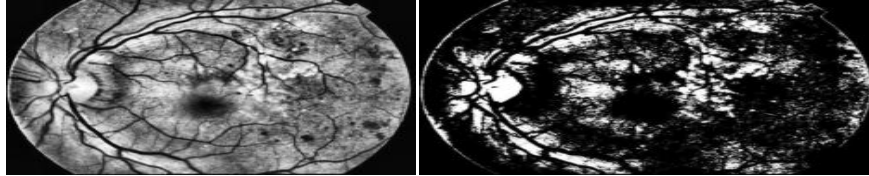


Fig.13(a) Image after twice AHE 13(b):Image after image segmentation

Where, M_{DAHE} = double adaptive histogram equalization. After this performs the image segmentation on fig.13(a) and obtained result is 13(b).

Identification of exudates are done by AND operation between image obtained after image segmentation fig.13(b) and the image after removing the large area fig.12(c). By AND operation the exudates are identified.

$$M_{EXUDATES} = \text{AND}(M_{IS}, M_L) \quad (9)$$

$M_{EXUDATES}$ = Image containing exudates, M_{IS} = Image obtained after image segmentation, M_L = Image obtained after removing large area.

Exudates are extracted hence to get the image which contains only micro-aneurysms are obtained as performing XOR operation between the $M_{EXUDATES}$ and also to the M_L .

$$M_{MA} = \text{XOR}(M_{EXUDATES}, M_L) \quad (10)$$

3.2.1 Removal of blood vessels:

Blood vessels are extracted after the image Fig.3(c) is applied with adaptive histogram equalization twice and image segmentation of another threshold value. A clearer image of blood vessels Fig.14(a) is acquired after removing the small area of noise.

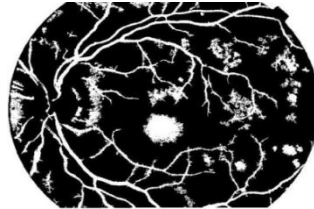


Fig.14(a): Blood Vessels after removing small area of noise

Blood vessels are extracted again by AND operation between the fig.14(a) and image after removing the large area fig.12(c). By doing this micro-aneurysms are detected.

$$M_{Micro} = \text{AND}(M_{BV}, M_L) \quad (11)$$

M_{Micro} = Micro-aneurysms partially obtained, M_{BV} = Blood Vessels after removing small area of noise.

3.3 Micro-aneurysms detection:

Detection of micro-aneurysms are done by AND operation between the micro-aneurysms obtained after the exudates filtering M_{MA} and to the micro-aneurysms obtained partially at blood vessels extraction M_{Micro} . where M_{FMA} = Final micro-aneurysms

$$M_{FMA} = \text{AND}(M_{MA}, M_{Micro}) \quad (12)$$



Fig.14(b): Final Micro-aneurysms

Now the area of the micro-aneurysms are calculated by considering the easy technique of detecting the diseased area parts and corresponding area is obtained by applying for loop for presence of pixels is considered as 1(white) and dark part as 0(black).

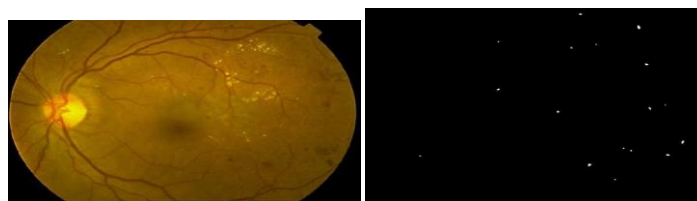


Fig 14(c) Fundus image (Left) with its micro-aneurysms image (Right)

IV. Results

This paper proposes the easy detection of exudates, blood vessels and micro-aneurysms and its area where the performance of the features are done on various images by the ophthalmologists. And the corresponding result of obtaining the exudates, blood vessels and micro-aneurysms from the retinal image done very efficiently. Here depending upon their areas disease severity of the patient is also identified

Patient Image	Input	Blood Vessels(B.V)	B.V Area	Exudates	Exudates Area	Micro aneurysms (M.A)	M.A Area	Disease Severity
			20123		198		96	Mild
			25864		1023		396	Moderate
			36845		2100		712	Severe
			19240		150		116	Mild
			39542		2012		725	Severe
			38956		1954		698	Severe
			22987		1125		495	Moderate


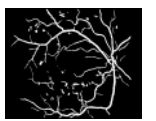


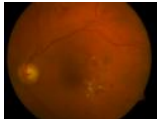



		40125		2765		954	Severe
		29541		1485		385	Moderate

Table.1: Comparison of patients input retinal image ,blood vessels ,blood vessels area ,exudates image ,exudates area , micro-aneurysms and its area and finally disease severity.

Hence the fig.7 illustrates the result of exudates detection fig.10(b) illustrates the result of blood vessels detection fig.14(c) illustrates the result of micro-aneurysms detection using k-means clustering.

And now the comparison of this results are done where tabular representation is considered for the of patients input retinal image ,blood vessels ,blood vessels area ,exudates image ,exudates area , micro-aneurysms and its area and finally disease severity.

V. Conclusion And Future Work

This paper proposes the easy detection of the exudates ,blood vessels and micro-aneurysms which are early stage for identification of diabetic retinopathy. This technique is undergone with specific steps where input retinal image is undergone with image pre-processing and next anatomical feature extraction later to extract the features image segmentation of k-means clustering is done followed by extraction of individual diseased areas such as exudates, blood vessels and micro-aneurysms from that unwanted features are filtered out and finally the corresponding features are detected and their area is calculated by considering the for loop. In future, the work can be extended about detecting the not only exudates, blood vessels and micro-aneurysms, but also the other features like haemorrhages and calculating the area depending upon which the severity of the disease can be identified.

References

- [1]. [1]SynaSreng, NoppadolManeerat, Kazuhiko Hamamoto, Automated Microaneurysms Detection in Fundus Images Using Image Segmentation 978-1-5090-5210-3/17/\$31.00 ©2017 IEEE
- [2]. [2] Dr. P.V. Rama Raju ,M.HarikrishnamRaju,M.Chanti:Image identification classification detection and obtaining 3D shape using removal technique and segmentation in international journal of control theory and applications(IJCTA) 5(3),45-52
- [3]. [3] Dr. P.V. Rama Raju ,T.Madhuri,T.LakshmiKanth,V.Ushasri:Human identification by segmentation and enhancement of Sclera using MATLAB in international journal of computational research(IJCER)6(4),2275-2280.
- [4]. [4] Jones CD, Greenwood RH, Misra A, Bachmann MO. Incidence and progression of diabetic retinopathy during 17 years of a population-based screening program in England. *Diabetes Care*. 35(3):592-6. Epub 2012/01/27.
- [5]. [5] A. Sopharak, B. Uyyanonvara, S. Barman, and T. Williamson, Automatic microaneurysm detection from non-dilated diabetic retinopathy retinal images. In *Proceedings of the World Congress on Engineering*, vol. 2, pp. 6-8. 2011.
- [6]. [6] R. Murugan, R. Korah, S.N. Fathima, and T. V. Haritha, Microaneurysmsdetection methods in retinal images using mathematical morphology. *Ophthalmology*, 110 (2003), 1679-80.
- [7]. [7] P. Yunuch, N. Maneerat, D. Isarakorn, B. Pasaya, R. Panjaphongse, andR. Varakulsiripunth. Automatic microaneurysms detection through retinalcolor image analysis. In *Information Technology and ElectricalEngineering (ICITEE)*, 2013 International Conference on pp. 36-40,IEEE, October 2013.
- [8]. [8] T. Inoue, Y. Hatanaka, S. Okumura, C. Muramatsu, and H. Fujita, Automated microaneurysm detection method based on eigenvalueanalysis using hessian matrix in retinal fundus images. In *Engineering inMedicine and Biology Society (EMBC)*, 2013 35th Annual InternationalConference of the IEEE, pp. 5873-5876, July 2013.
- [9]. [9] T. Walter, P. Massin, A. Erginay, R. Ordonez, C. Jeulin and J. C. Klein, Automatic detection of microaneurysms in color fundus images. *Medicalimage analysis*, 11(6) (2007), 555-566.:

International Journal of Engineering Science Invention (IJESI) is UGC approved Journal with Sl. No. 3822, Journal no. 43302.

Dr. P.V.Ramaraju "Disease Severity Based On Areas of Exudates, Blood Vessels And Micro-Aneurysms In Retinal Fundus Images Using K-Means Clustering" International Journal of Engineering Science Invention (IJESI), vol. 07, no. 02, 2018, pp. 69-77.